



[ANIMAL HEALTH & WELFARE \(/ADVOCATE/CATEGORY/ANIMAL-HEALTH-WELFARE\)](#)

---

# White tail disease in shrimp mimics infectious myonecrosis

Thursday, 1 May 2008

By Donald V. Lightner, Ph.D. , Carlos R. Pantoja, Ph.D. , Rita M. Redman , Brenda L. Noble , Paul J. Schofield and Kathy F.J. Tang, Ph.D.

## IMN first appeared in Brazil in 2002



These juvenile *Penaeus vannamei* exhibit muscle necrosis, especially in the abdomen, due to infection by PvNV. The top shrimp shows severe generalized necrosis and opacity, while the others have more defined areas of muscle necrosis.

Muscle necrosis in shrimp often results in the appearance of opaque white lesions in the tail muscle in response to environmental factors such as low dissolved oxygen, sudden changes in temperature or salinity, or other stress. Severe hypoxia, a shortage of oxygen in tissue, can occur in the terminal phase of many infectious diseases and result in necrosis of abdominal muscles. White muscles in shrimp also can result from advanced infections by microsporidians belonging to the genera (*Ameson*) and (*Agmasoma*), or dietary deficiency of selenium.

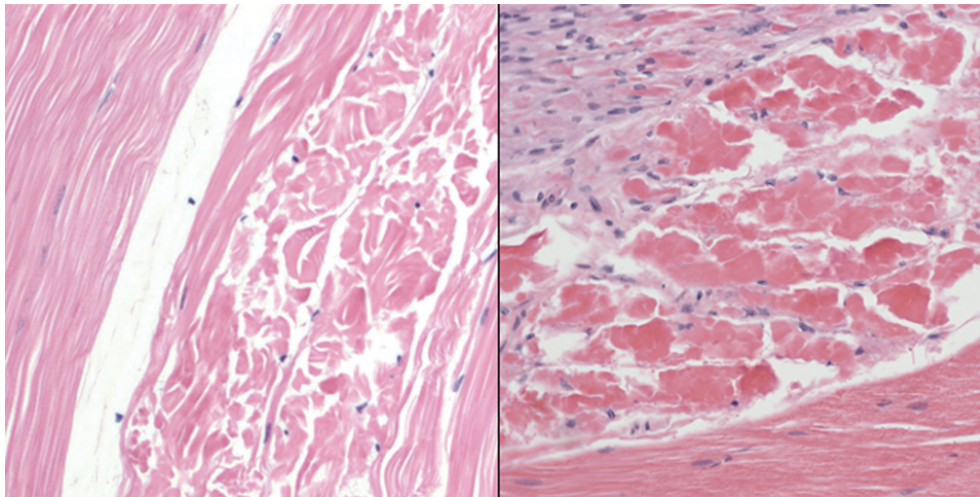
## Infectious myonecrosis virus

In 2004, Infectious Myonecrosis Virus (IMNV) was isolated from *Penaeus vannamei* farmed in Brazil and named after the muscle necrosis it causes. Since its appearance in about 2002 in northeastern Brazil, Infectious Myonecrosis (IMN) has been a significant disease of *P. vannamei*.

By 2006, it had spread to Southeast Asia. Anecdotally said to have been transferred there with *P. vannamei* broodstock from Brazil, IMN caused significant losses in Indonesia. Because of its demonstrated ability to cause significant production losses and potential for further spread globally, IMN was added to the diseases listed by the Office International des Epizooties (World Organization for Animal Health) in 2007.

## Penaeid white tail disease

Not long after IMN spread through several of the major shrimp-growing states in northeastern Brazil, the **Aquaculture Pathology Laboratory** (<https://www.aquaculturealliance.org/advocate/history-future-aquaculture-pathology-laboratory/>), at the University of Arizona in Tucson, Arizona, USA, began receiving diagnostic case submissions of shrimp presenting white muscle lesions from Latin American countries besides Brazil. While none of the cases was caused by **IMNV** (<https://www.aquaculturealliance.org/advocate/brazil-shrimp-farm-performs-genetic-selection-imnv-resistance-growth/>), and most presented case histories and pathology consistent with hypoxia due to stressful environmental conditions or terminal hypoxia from other diseases, a few samples from Belize and later Nicaragua presented lesions that histologically matched those of IMNV infection but were found negative for IMNV infection by real-time polymerase chain reaction and in situ hybridization assays.



Microscopic examination illustrates acute necrosis in the skeletal muscles of shrimp caused by IMNV on the left and PvNV on the right.

Initially, the “Belize agent” was thought to be a genetic variant of IMNV. However, when the Belize agent was isolated from diseased shrimp and subsequently characterized, it was found to be a nodavirus. Its closest relative is *Macrobrachium rosenbergii* Nodavirus, the cause of White Tail Disease (WTD) in *M. rosenbergii*, which has occurred in freshwater prawn hatcheries and farms in the Caribbean, India and East Asia.

The virus from *P. vannamei* was therefore named *Penaeus vannamei* Nodavirus or PvNV, and the disease it causes was named Penaeid White Tail Disease (PWTD), to distinguish it from IMN and White Tail Disease in macrobrachium. Molecular tests for PvNV were developed to aid in diagnosis of PWTD and detection of PvNV.

## Low prevalence

Subsequent application of these diagnostic tools to case submissions of shrimp with white muscles and surveys of *P. vannamei* from Central and South America have suggested that PWTD occurs at generally very low prevalence, even in Belize. It may not be a significant disease of *P. vannamei*, except possibly under certain yet-to-be-determined severe stress conditions.

Furthermore, PvNV has not been detected in samples submitted for diagnosis from farms in Central or South America, except from Belize and an adjacent area of Nicaragua. Hence, although PWTD presents signs very similar to those of shrimp with IMN, a much more serious disease, it does not pose a serious threat to *P. vannamei* grown under current farming conditions.

PvNV and the disease it causes would very likely have not have been discovered had shrimp with PWTD not drawn the attention of worried shrimp farm personnel because its gross signs mimic those presented with IMN.

*(Editor's Note: This article was originally published in the May/June 2008 print edition of the Global Aquaculture Advocate.)*

## Authors

---



**DONALD V. LIGHTNER, PH.D.**  
Aquaculture Pathology Laboratory  
Department of Veterinary Science and Microbiology  
University of Arizona  
Tucson, Arizona 85721 USA  
[dvl@u.arizona.edu](mailto:dvl@u.arizona.edu) (<mailto:dvl@u.arizona.edu>).



**CARLOS R. PANTOJA, PH.D.**  
Aquaculture Pathology Laboratory  
Department of Veterinary Science and Microbiology  
University of Arizona  
Tucson, Arizona 85721 USA



**RITA M. REDMAN**  
Aquaculture Pathology Laboratory  
Department of Veterinary Science and Microbiology  
University of Arizona  
Tucson, Arizona 85721 USA



**BRENDA L. NOBLE**

Aquaculture Pathology Laboratory  
Department of Veterinary Science and Microbiology  
University of Arizona  
Tucson, Arizona 85721 USA



**PAUL J. SCHOFIELD**

Aquaculture Pathology Laboratory  
Department of Veterinary Science and Microbiology  
University of Arizona  
Tucson, Arizona 85721 USA



**KATHY F.J. TANG, PH.D.**

Aquaculture Pathology Laboratory  
Department of Veterinary Science and Microbiology  
University of Arizona  
Tucson, Arizona 85721 USA

Copyright © 2016–2019  
Global Aquaculture Alliance