



[ANIMAL HEALTH & WELFARE \(/ADVOCATE/CATEGORY/ANIMAL-HEALTH-WELFARE\)](#)

Probiotics benefit Pacific white shrimp challenged with AHPND

Thursday, 26 May 2016

By Dang Thi Hoang Oanh, Ph.D. , Mathias Corteel, Ph.D. and Olivier Decamp, Ph.D.

Researchers note higher survival and histological signs of hepatopancreas regeneration in Vietnam trials with INVE



This study showed that commercial probiotics treatments had beneficial effects for Pacific white shrimp, including higher survival and histological signs of hepatopancreas regeneration.

Early mortality syndrome (EMS) is a management syndrome. A combination of adverse factors in nutrition, biosecurity, host physiology, and especially microbial management leads to a situation in which opportunistic pathogens such as *Vibrio parahaemolyticus* can bloom and dominate the microbiota around and inside the shrimp. When additional virulence factors such as colonization of the stomach and toxin production are added to this setting, diseases such as acute hepatopancreas necrosis (AHPND) will cause severe losses.

INVE Aquaculture has already been working on this issue for more than a decade, in the context of “traditional” vibriosis. Hence it was a logical step to extrapolate our established pro- and metaphylactic treatments to this new variant of *Vibrio*. When applying our probiotics in the field, as part of a holistic intervention protocol, a significant amount of empirical data of the beneficial action of *Bacillus* probiotics during shrimp culture has been collected. In this study our objective was to measure the effects of Sanolife probiotics in a standardized AHPND challenge model under controlled laboratory conditions.

Test shrimp

Pacific white shrimp (*Litopenaeus vannamei*) were bred and nursed at the shrimp hatchery and nursery of the College of Aquaculture and Fisheries, Can Tho University. Shrimp stocks were under surveillance for WSSV, YHV (IQ2000 YHV/GAV) and AHPND *Vibrio* to maintain SPF status.

For this study, shrimp around PL20-25 stage, with an average body weight around 1 g were used, the age and size which is most affected by EMS/AHPND under culture conditions. Natural seawater was used throughout the experiments, sterilized and diluted to 25 g/L, a typical salinity for *P. vannamei* grow-out. This study was originally published in *Aquaculture Asia Pacific* 11(6):14-17.

Bacteria

We designated the bacterial strain used in this study as LTS14. It was originally isolated from shrimp diagnosed with AHPND (histo)pathology in Vietnam in May 2014 and stored at -80°C in TSB supplemented with 1.5 percent NaCl and 25 percent glycerol. The bacteria were identified as *V. parahaemolyticus*, by green colonies on TCBS, conventional API 20E biochemical tests and PCR with LTH primers. Additionally, the isolate was positive on PCR with AP3 primers.

Prior to the study, the virulence of LTS14 was extensively evaluated by *in vivo* challenges, and compared to other strains. The challenge dose was fine-tuned in order to obtain a reproducible sub-acute LD₅₀₋₆₀ mortality curve (Figure 1).

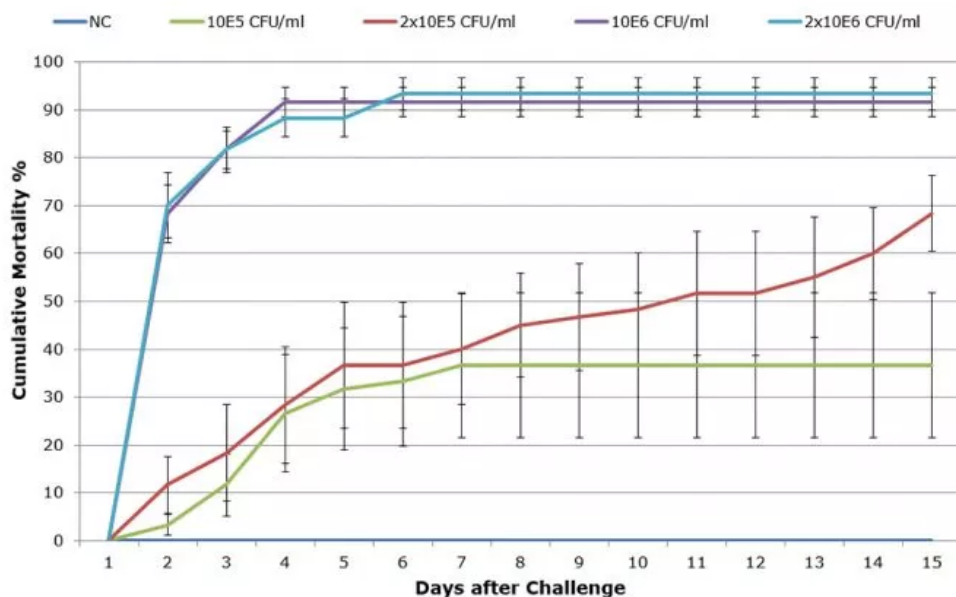


Fig. 1: Cumulative mortality curves of the *in vivo* titration of *V. parahaemolyticus* LTS14. Each dose was administered to 6 replicate

tanks with 10 shrimp. Based on this experiment, the dose of 2×10^5 CFU ml⁻¹ was selected for further challenges, due to its sub-acute course.

Challenge

Bacterial cultures were grown 24 hours in TSB supplemented with 1.5 percent NaCl at 28°C. Based on the standard curve determined for the strain, the bacterial suspension was diluted in sea water to an OD corresponding to 10^8 cells ml⁻¹. Shrimp were immersed for 15 minutes in this bacterial culture with continuous aeration and then both bacterial solution and shrimp were transferred to aquaria containing sea water, reducing the bacterial concentration to 10^5 , 2×10^5 , 10^6 , 2×10^6 cells/mL. No water was exchanged until two days after the challenge, from which point 20 percent of water was renewed daily.

Experimental design

Experimental shrimp were stocked at a density of 30 individuals per aquarium with 30 liters of water, continuous aeration and water parameters held constant at $29 \pm 1^\circ\text{C}$, pH 7.7 ± 2 , $\text{NH}_3 < 0.1$ mg/L and DO 4 mg/L by daily water exchange.

The following five treatments in triplicate were compared:

Treatment description	Challenge with <i>V. parahaemolyticus</i>
Negative control (NC)	-
Positive control (PC)	+
Antibiotic control (AB) doxycycline 2g kg ⁻¹ feed	+
Sanolife PRO-2 (PRO-2) 10g kg ⁻¹ feed	+
Sanolife PRO-W (PRO-W) 5 mg l ⁻¹	+

Feed applications were top-coated with every ration and the Sanolife PRO-W water application was added to the water of the aquarium once per day. The dose of Sanolife PRO-2 was 2×10^8 CFU *Bacillus* per g feed and the dose of Sanolife PRO-W was 2.5×10^5 CFU *Bacillus* per ml water. Apart from the NC, all shrimp were challenged with 2×10^5 CFU/mL of LTS14, and clinical follow-up was performed for 15 days after challenge.

The evaluation of the treatments was based on statistical comparison of: (1) the severity and time of onset of clinical signs; (2) the cumulative mortality; and (3) the severity of score on histopathology.

Severity of clinical signs AHPND

Clinical signs such as anorexia, lethargy and pale coloration of the body and hepatopancreas were observed in 75 percent of the animals in the positive control group as early as 24 hours after the challenge. Shrimp in the AB and Sanolife PRO-W groups also demonstrated AHPND symptoms, but with less pronounced anorexia, and in a reduced group of animals (50 percent). Less than 20 percent of shrimp receiving Sanolife PRO-2 were recorded with AHPND symptoms, and with a significant delay of 72h after challenge. Representative photos of gross signs are shown in Figure 2.




Fig. 2: Gross signs 48 hours after challenge with 2×10^5 CFU/ml *V. parahaemolyticus* LTS14. (A) negative control (NC) shrimp, (B) positive control (PC) shrimp, (C) Sanolife PRO-2 treated shrimp. Gross signs of AHPND: absence of feed in gut, pale discoloration and atrophy of the hepatopancreas can be clearly noted in the PC shrimp. Disease signs were delayed and attenuated in the Sanolife PRO-2 treated animals.

Reduced mortality

Mortality started in the PC group 1 dpi (days post-inoculation) and reached a cumulative mortality of 52 ± 10 percent after 10 days (Figure 3). In AB and Sanolife PRO-W groups, mortality also started at 1 dpi and cumulative mortality attained 32 ± 12 percent and 34 ± 5 percent respectively. A delay in mortality of 4 days was noted for the Sanolife PRO-2 group, with cumulative mortality stopping at 17 ± 3 percent after 9 days. The Sanolife PRO-2 result was statistically significantly lower than the PC, but also still higher than the NC 3 ± 3 percent.

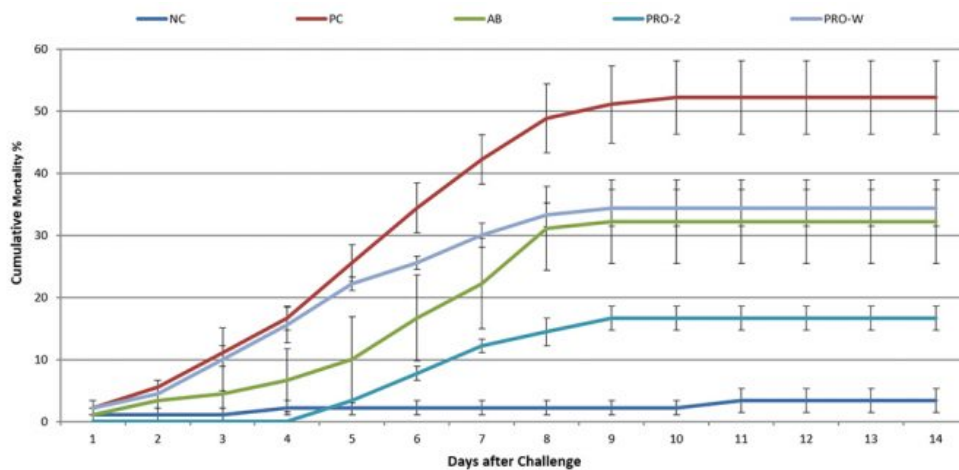


Fig. 3: Cumulative mortality curves of treatment groups after challenge with 2×10^5 CFU/ml *V. parahaemolyticus* LTS14. NC: negative control, PC: positive control, AB: doxycycline 2g/kg feed, Sanolife PRO-2: 10g/kg feed, Sanolife PRO-W: 5 mg/L rearing water.

Histopathology

Representative images of histopathological analysis of shrimp in the different treatments.

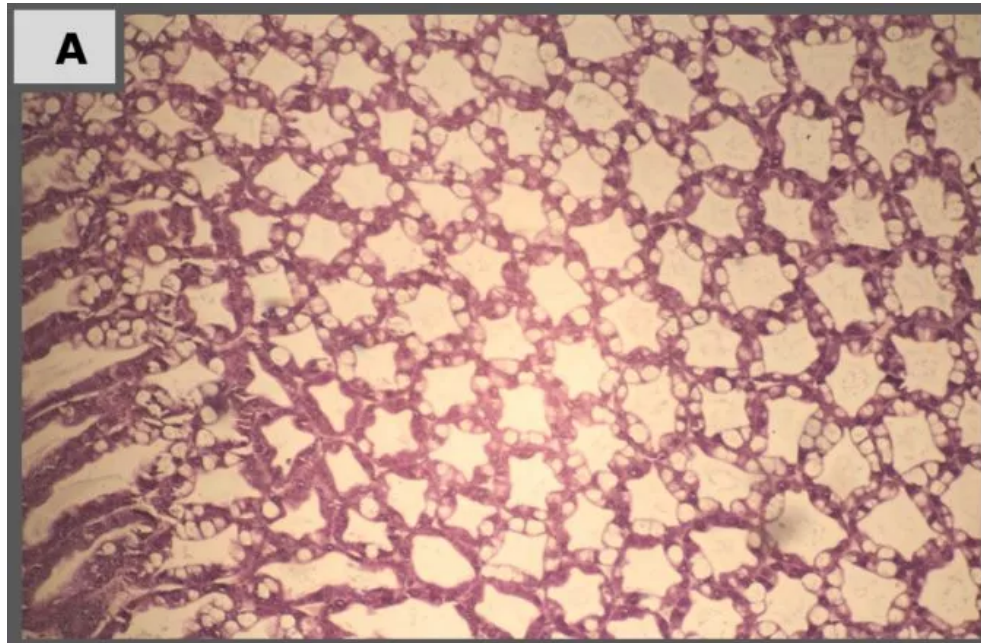


Fig. 4A: Negative control: normal histology hepatopancreas, with differentiated cell types, notable B-cells with vacuoles.

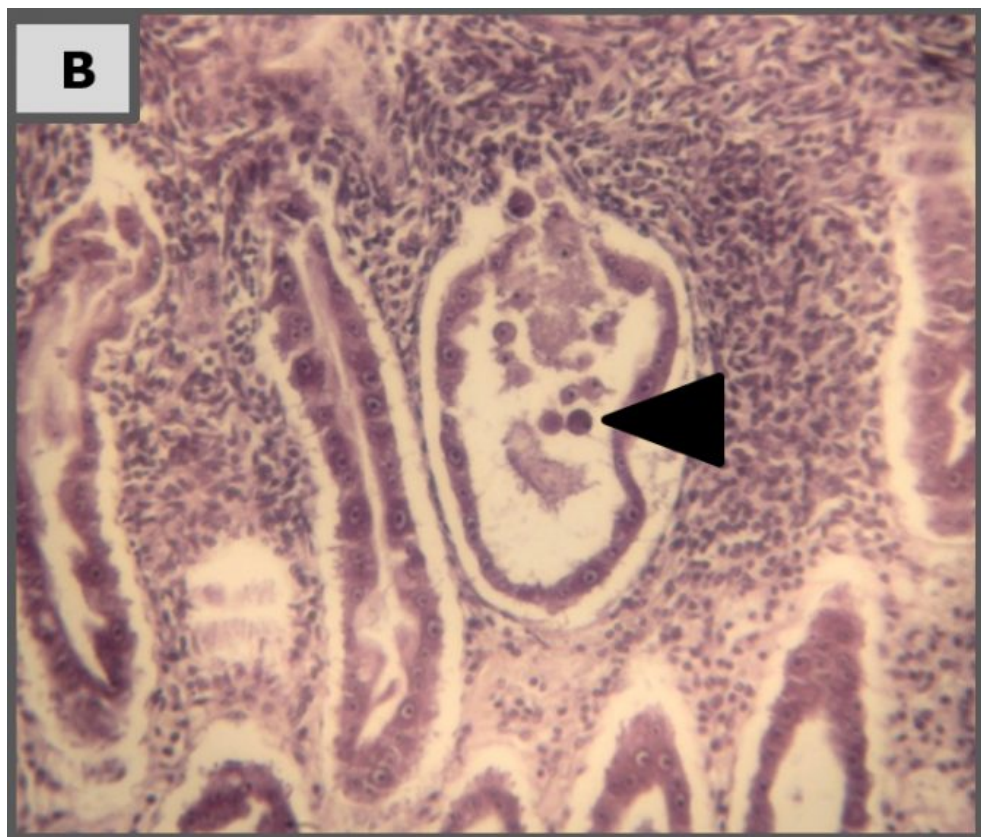


Fig. 4B: Positive control (4 dpi): Rounding and sloughing of hepatopancreas epithelium cells due to *V. parahaemolyticus* toxin (arrowhead) in a necrotizing tubule, surrounded by thick hemocytic encapsulation.

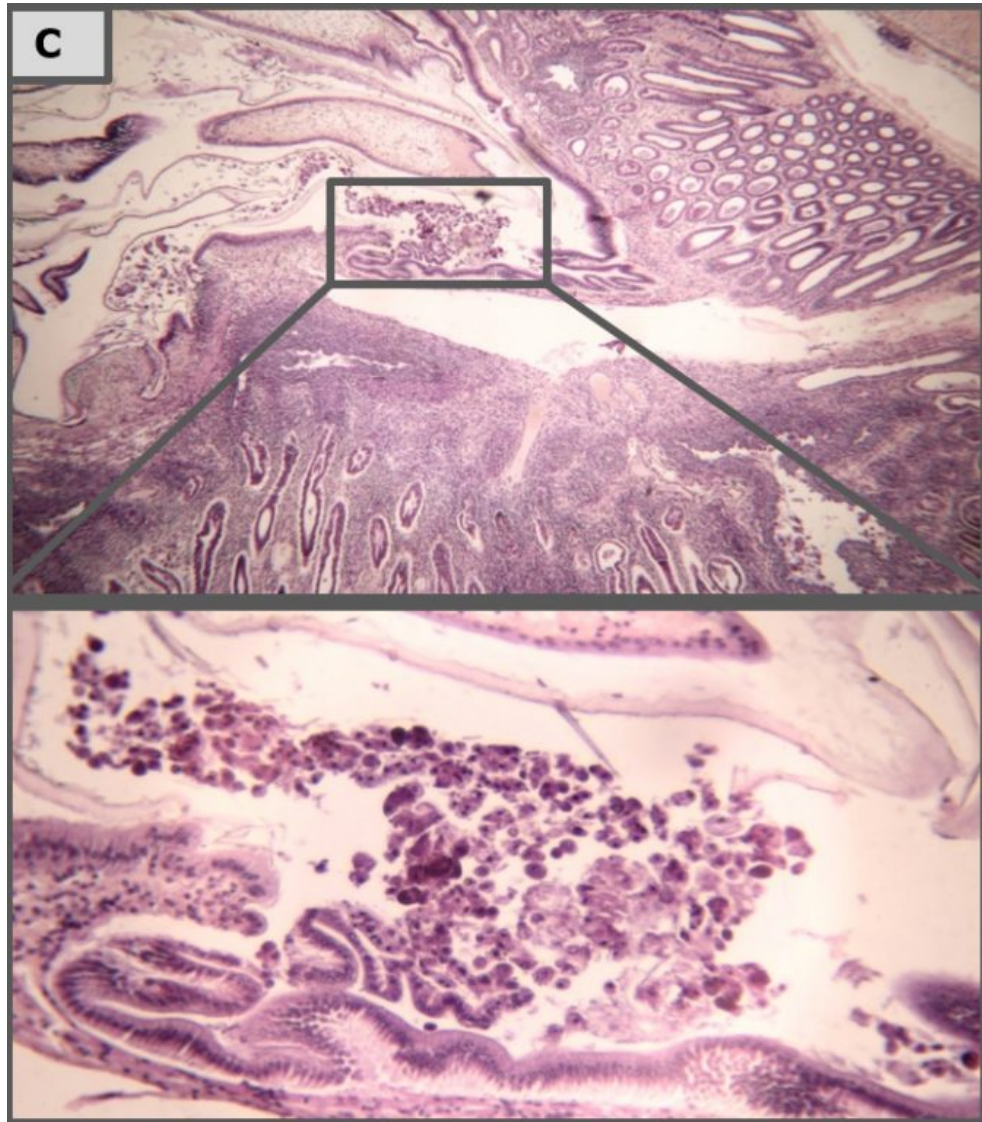


Fig. 4C: Positive control (10 dpi): severe hemocytic infiltration around hepatopancreas tubuli, sloughing of cells out of the hepatopancreas into the stomach combined with loss of cell types (B-, F- and R-cells).

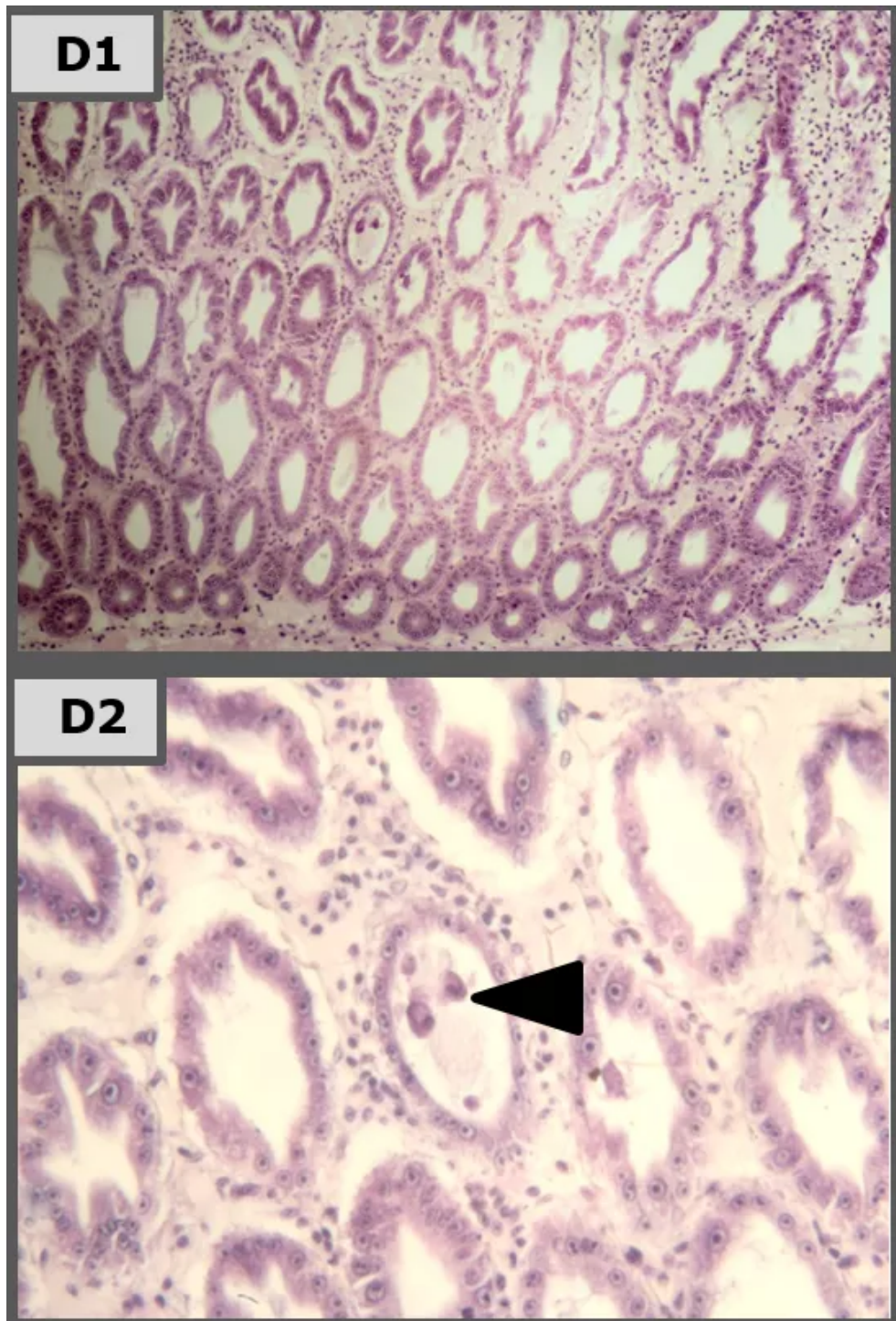


Fig. 4D: Sanolife PRO-2 (10 dpi): Rounding and sloughing of hepatopancreas epithelium cells was observed sporadically (arrowhead D2). Epithelium height was reduced compared to NC, but loss of cell type differentiation was less pronounced (mainly less B-cells). Hemocytic infiltration was less profuse, with interstitial space appearing more fibrous.

Perspectives

The AHPND challenge model developed and standardized for this study resulted in a mortality curve of the positive control which reaches its maximum after several days, and does not wipe out all the inoculated shrimp. This is more in line with AHPND outbreaks in shrimp farms and also offers a better chance for evaluating possible therapeutic interventions than many reported challenge models employing impossibly high bacterial concentrations and resulting in hyper-acute mortality.

The results of our laboratory study show that Sanolife PRO-2 and Sanolife PRO-W probiotics treatments by themselves have beneficial effects, such as higher survival and histological signs of hepatopancreas regeneration. However, similar to antibiotic treatments, probiotic treatments are not sufficient to completely protect shrimp from disease. For this, a holistic approach is needed, supporting and correcting the rearing system and the shrimp's health status on all levels.

Authors



DANG THI HOANG OANH, PH.D.

Head, Department of Aquatic Pathology
College of Aquaculture and Fisheries
Cantho University
3-2 Street, Ninhkieu District
Cantho City, VIETNAM

dthoanh@ctu.edu.vn (mailto:dthoanh@ctu.edu.vn)



MATHIAS CORTEEL, PH.D.
R&D Engineer
INVE Aquaculture,
Hoogveld 93, 9200 Dendermonde
BELGIUM
m.corteel@inveaquaculture.com (mailto:m.corteel@inveaquaculture.com).



OLIVIER DECAMP, PH.D.
Product Manager Health
INVE Aquaculture
Hoogveld 93, 9200 Dendermonde
BELGIUM
o.decamp@inveaquaculture.com (mailto:o.decamp@inveaquaculture.com).