



[ANIMAL HEALTH & WELFARE \(/ADVOCATE/CATEGORY/ANIMAL-HEALTH-WELFARE\)](#)

---

# Parasite treatment reduces *F. columnare* infection in tilapia

Thursday, 19 November 2015

By De-Hai Xu, Ph.D. and Craig Shoemaker, Ph.D.; Dunhua Zhang, Ph.D.

## Columnaris disease troublesome for freshwater fish culture

*Trichodina* are ciliated protozoan parasites of fish commonly found on the skin and gills. Fry and fingerling fish are especially susceptible to parasitism by *Trichodina*. *Trichodina* causes irritation by feeding on the epithelial layers of cells covering the surfaces of the skin and gills of the fish. *Trichodina* can cause serious pathological changes and mortalities among heavily parasitized fish. High numbers of *Trichodina* on fish can result in abrasion with the development of lesions and ulcers that allow secondary bacterial infections to develop.

*Flavobacterium columnare*, a Gram-negative rod bacterium, is the causative agent of columnaris disease. It frequently causes high mortality in many commercially important freshwater fish worldwide, including tilapia. Columnaris affects all life stages, from newly hatched fry to fish that have reached market size. Columnaris is generally regarded as an external infection of fish with clinical signs of skin lesions, fin erosion and gill necrosis.



The authors treated *Trichodina* with formalin in tilapia and determined fish survival following a bacterial challenge with *F. columnare*.

## Concurrent disease

Parasites and bacteria are common inhabitants in water at fish farms. Studies of parasite-bacteria interactions have showed that concurrent infections increase the severity of some infectious diseases, especially bacterial diseases.

In a previous report, tilapia infected with high numbers of *Trichodina* at a recirculation production facility had skin injuries that led to bacterial streptococcosis and edwardsiellosis that could not be controlled by antibiotics. Control of the parasite with formalin resulted in a decrease in overall deaths.

## Treatment study

Building on this, the authors performed a study to evaluate whether treatment of *Trichodina*-parasitized tilapia with formalin would reduce *F. columnare* infection in fish and ultimately result in improved fish survival.

Sex-reversed hybrid tilapia of about 10-cm length reared in three, 340-L indoor tanks at the Aquatic Animal Health Research Unit of the U.S. Department of Agriculture's Agricultural Research Service in Auburn, Ala., were found to be parasitized with *Trichodina* on both skin and gills. The infection intensity was measured at 4 to 8 *Trichodina* within a single 100-time magnification view under a microscope.

*Flavobacterium columnare* was isolated from a diseased channel catfish from Alabama. The isolate was inoculated in broth and incubated aerobically at 28 degrees-C. Following 24 hours of growth, the concentration of the bacterium was determined by bacterial plate count.

## Parasite treatment

A total of 390 hybrid tilapia were divided into three groups. One group received no parasite treatment. The second group was treated in a single water bath with 150 mg/L formalin for one hour. The third was treated in a water bath with 150 mg/L formalin for one hour on two consecutive days. The fish were allowed to recover for five days after the treatments.

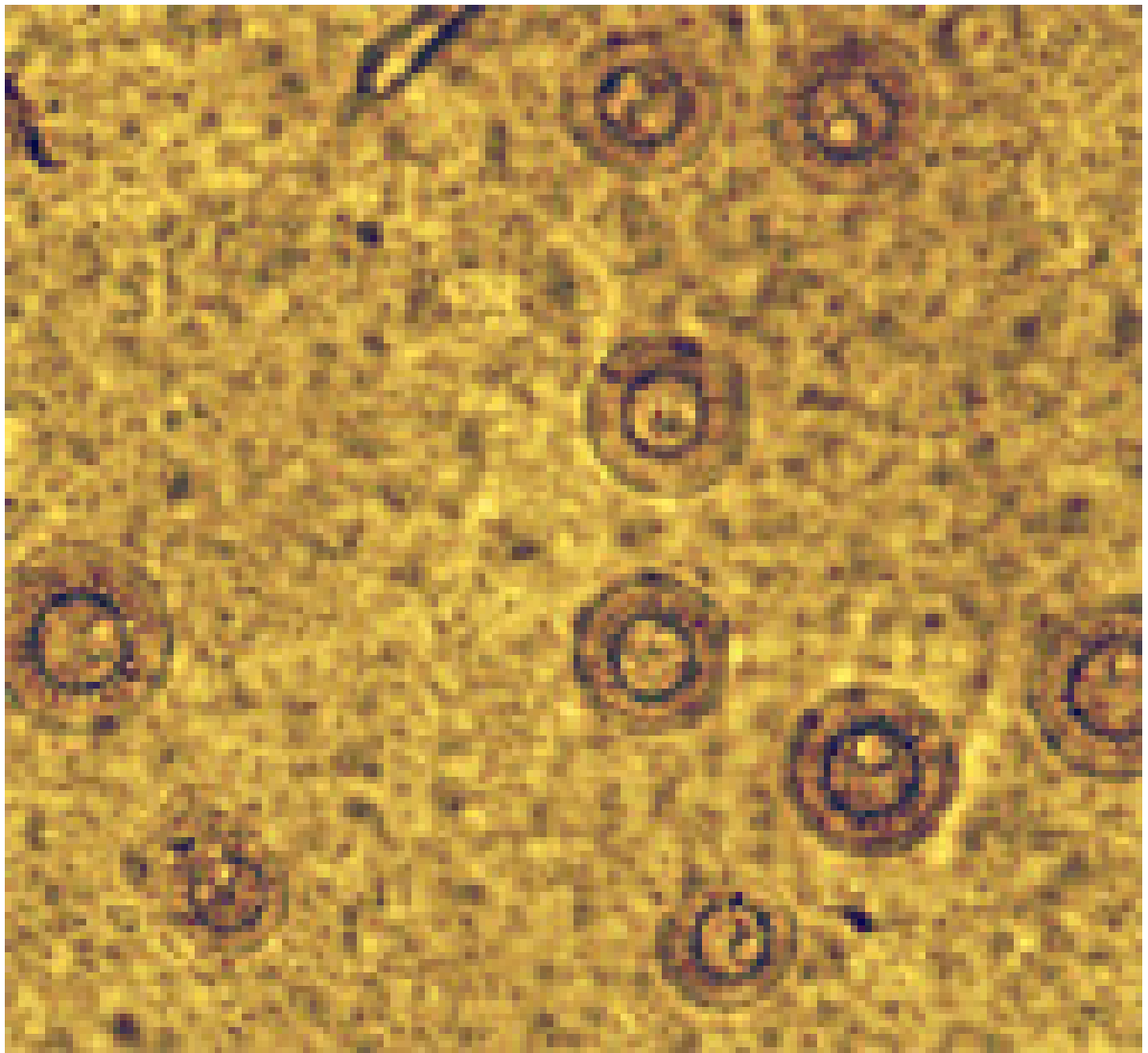
Ten fish were sampled from each group to enumerate their parasite loads and verify the fish were not infected with *F. columnare* using real-time polymerase chain reaction (qPCR). The fish were then divided into 18 tanks at 20 fish/tank for *F. columnare* challenge.

## *F. columnare* challenge

Each group of fish from the formalin treatment phase was stocked in triplicate tanks. Half of each group was challenged via immersion in buckets of water with *F. columnare* at a concentration of  $3.2 \times 10^7$  colony-forming units (CFU)/mL for 15 minutes. The remaining fish were not exposed to the bacteria, but kept in water with the same amount of Shieh broth for the same duration.

Two fish were randomly sampled from each tank one and three days after the *F. columnare* exposure. To evaluate *Trichodina* infection, wet-mount samples of skin and gill filaments were observed under a microscope.

Gill, liver and kidney tissues of about 20 mg were then collected from two fish and macerated in a microcentrifuge tube for *F. columnare* quantification. DNA was extracted and purified using standard methods. qPCR testing was used to quantify the *F. columnare* in infected fish.



This magnified wet-mount sample shows *Trichodina* infection on tilapia caudal fin tissue.

## Results

Prior to the *F. columnare* challenge, no *Trichodina* was observed five days post parasite treatment on the skin and gills of fish that were treated twice with formalin (Table 1). The single formalin treatment significantly reduced parasite prevalence and intensity as compared to the untreated fish. All non-treated fish were infected by *Trichodina* at an intensity of 4-6 parasites/viewing area.

No. of treatments	No. of fish	Infection prevalence (%)	Infection intensity
Prior to <i>F. columnare</i> challenge			
0	30	100	6.4
1	30	20	0.3

2	30	0	0
One day after <i>F. columnare</i> challenge			
0	18	100	3.7
1	18	22	0.2
2	18	0	0

After exposure to *F. columnare*, the untreated tilapia parasitized by *Trichodina* showed 37.5 percent mortality, while mortality for those treated with formalin was 16.7 percent or less (Table 2). Tilapia treated twice experienced 6.4 percent mortality. No mortality was observed in the parasitized tilapia that were not challenged with *F. columnare*.

No. of treatments	<i>F. columnare</i> challenge	No. of fish	No. of dead	Mortality (%)
0	Yes	48	18	37.5
1	Yes	48	8	16.7
2	Yes	48	3	6.3
0	No	48	0	0
1	No	48	0	0
2	No	48	0	0

One day after exposure to *F. columnare*, the parasitized fish without treatment showed significantly higher numbers of *F. columnare* in their gills compared to those treated with formalin (Table 3). The bacterial load was 27,075 genome copies (G.C.)/mg in the gills of parasitized fish without treatment – 12-fold higher than those treated once with formalin (2,250 G.C./mg) or 39-fold higher than those treated twice with formalin (699 G.C./mg).

Tissue	Treatment	G.C./mg
Gill	0	27,075
	1	2,250
	2	699
Kidney	0	207
	1	88
	2	0
Liver	0	266
	1	127
	2	0

The parasitized fish without treatment also showed higher bacterial numbers in kidney and liver tissue than those treated with formalin, with concentrations of 207 and 266 G.C./mg, respectively.

Fish treated once with formalin had bacterial concentrations of 88 G.C./mg in kidney tissue and 127 G.C./mg in liver tissue. No *F. columnare* was detected in kidney and liver of fish treated twice.

## Perspectives

*Trichodina* are transmitted by fish-to-fish contact and/or contaminated water. Improving water quality could be effective in reducing parasite infections in farmed fish. When fish parasites are detected in pond fish, treatment may be considered if the parasites are treatable, and treatments are economically feasible. Early detection and treatment may prevent heavy parasite loads on fish and limit the spread of parasites to fish in other tanks or ponds.

Parasite infections can disrupt the first line of defense in the skin and gills of fish, thereby creating portals of entry for bacterial pathogens. The formalin treatment of *Trichodina*-parasitized fish reduced bacterial invasion and ultimately improved fish survival.

This work suggested that prevention and treatment of parasite infections in fish are important parts of fish health management that not only reduce the direct damage caused by parasites, but also reduce fish mortality due to secondary bacterial infection.

## Authors

---



**DE-HAI XU, PH.D.**

USDA Agricultural Research Service  
Aquatic Animal Health Research Unit  
990 Wire Road  
Auburn, AL 36832  
USA

[dehai.xu@ars.usda.gov](mailto:dehai.xu@ars.usda.gov) (<mailto:dehai.xu@ars.usda.gov>)



**CRAIG SHOEMAKER, PH.D.; DUNHUA ZHANG, PH.D.**

USDA Agricultural Research Service  
Aquatic Animal Health Research Unit

Copyright © 2016–2019  
Global Aquaculture Alliance