



[ANIMAL HEALTH & WELFARE \(/ADVOCATE/CATEGORY/ANIMAL-HEALTH-WELFARE\)](#)

---

# New management tools for EHP in penaeid shrimp

Friday, 15 April 2016

By Jee Eun Han, Ph.D. , Kathy F.J. Tang, Ph.D. and Donald V. Lightner, Ph.D.

## In situ hybridization and PCR effective at detecting microsporidian parasite

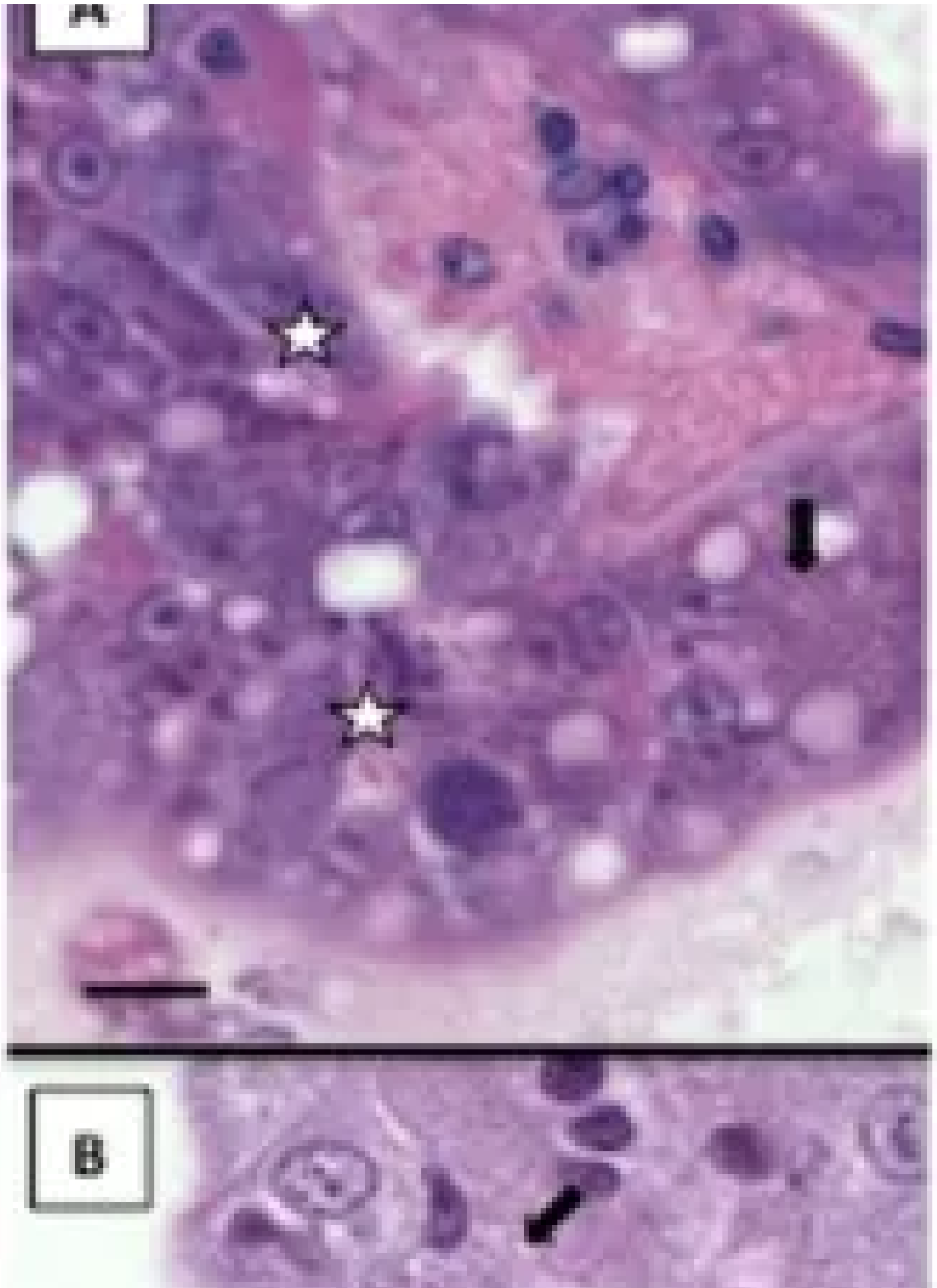
In penaeid shrimp, microsporidia infect host tissues such as muscle, heart, gonads, gills, hepatopancreas, and nerve ganglia, depending on the type of microsporidia. Shrimp microsporidia are considered a potential threat for their populations, and also lead an economic impact in aquaculture. Recently, a microsporidium, *Enterocytozoon hepatopenaei* (**EHP** (<https://www.aquaculturealliance.org/advocate/ehp-risk-factor-shrimp-diseases/>)), that replicates within the cytoplasmic area of the tubule epithelial cells in the hepatopancreas has been found in several shrimp farming countries in Asia including Vietnam, Thailand, Malaysia, Indonesia, China and India. The clinical signs of the EHP infection are not specific, and associated with growth retardation.

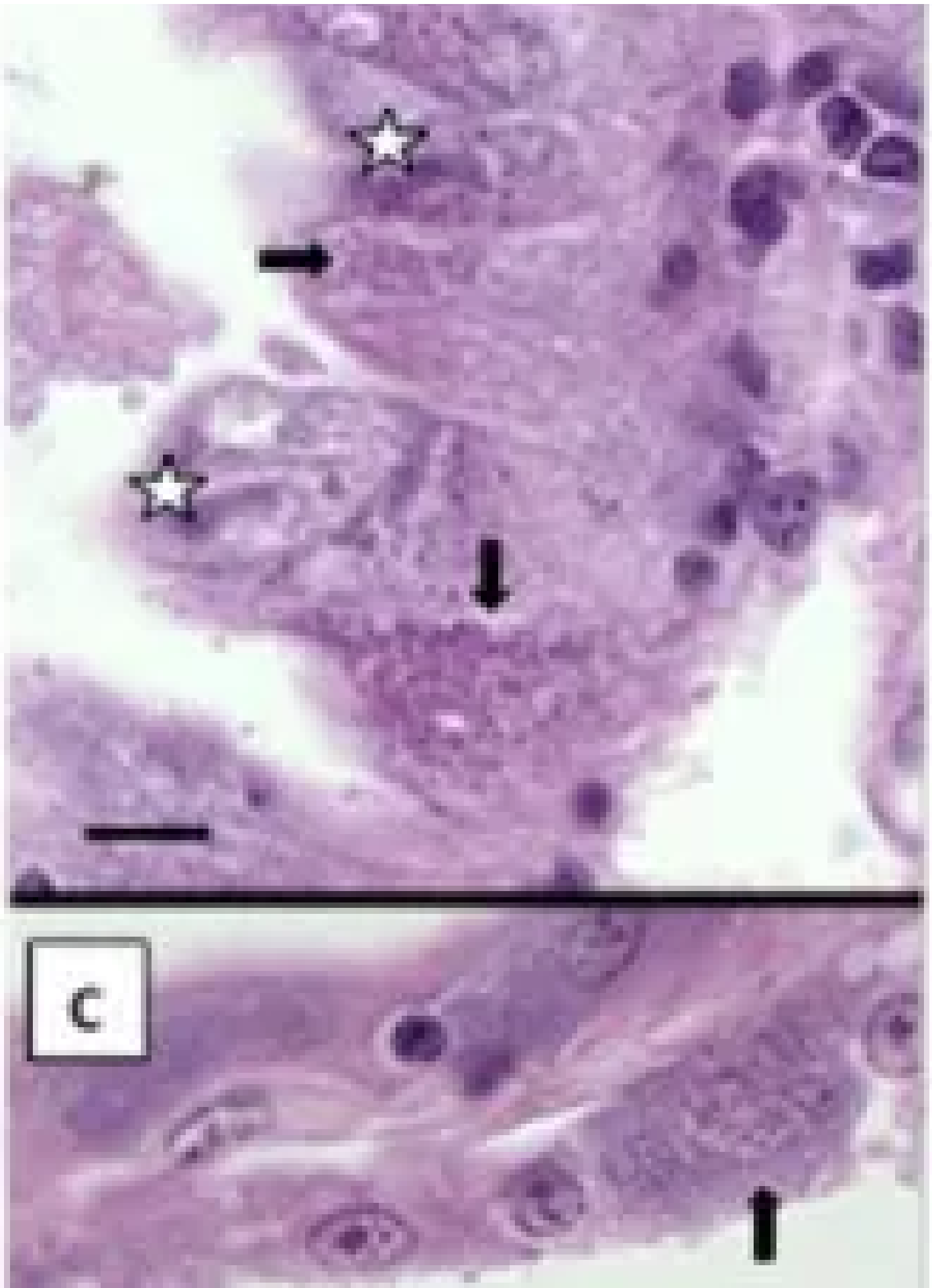


The emerging microsporidian parasite, *Enterocytozoon hepatopenaei* (EHP) causes serious production losses to shrimp farmers in many parts of the world. The assay methods described here are new, important management tool to manage this new shrimp disease.

## Histopathology of EHP

Histological examination of samples of EHP-infected *Penaeus vannamei* from Vietnam (2014) showed basophilic inclusions within the cytoplasm of hepatopancreas tubule epithelial cells of (Fig 1A & 1B). These inclusions appeared to be at plasmodia stage; mature, basophilic, spores were also observed. The EHP-infected *P. stylirostris* collected in Brunei (2006) were also showed the presence of microsporidium spores within the hepatopancreas (Fig. 1C). These results also indicate that EHP has been present in Asia since 2006.





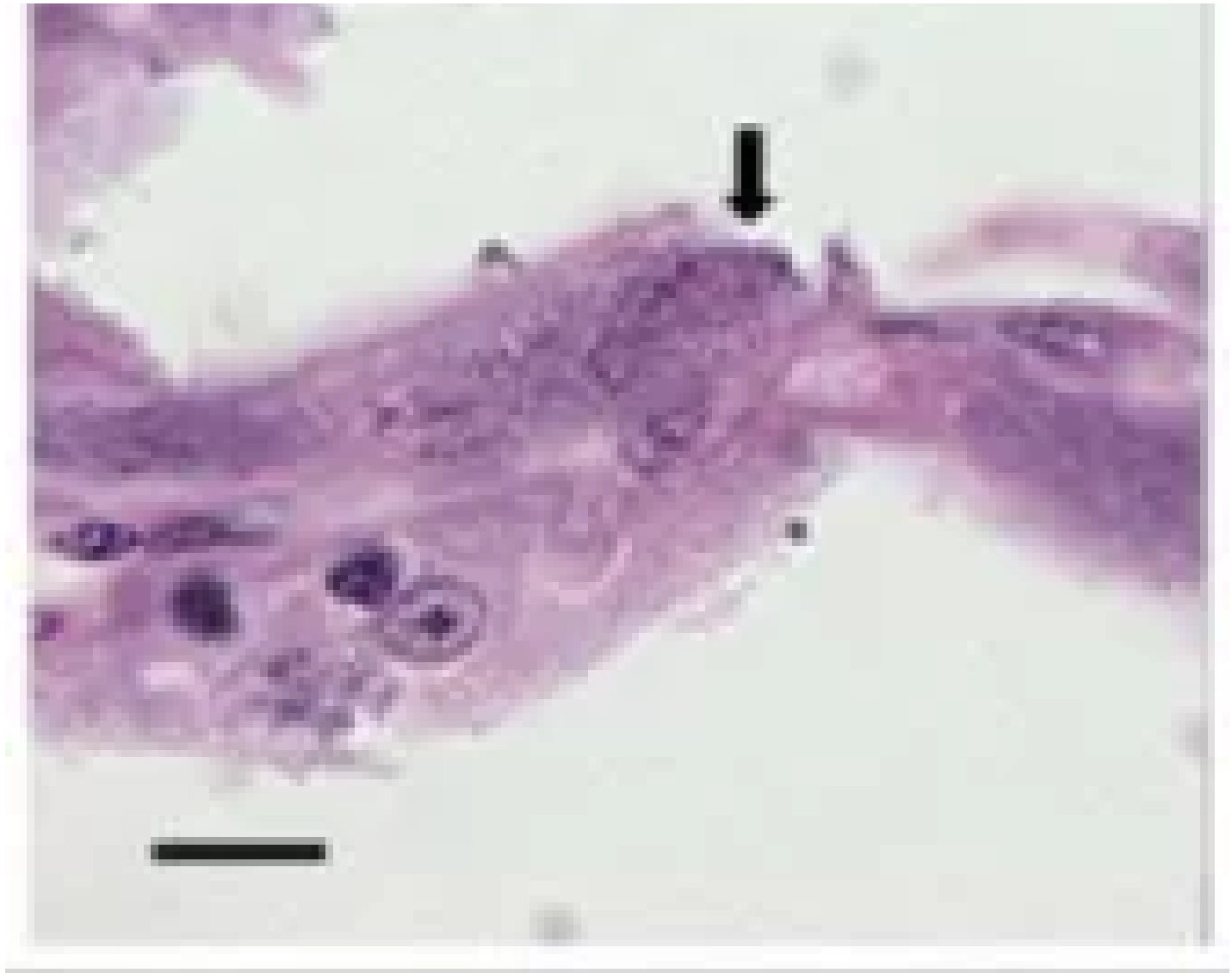
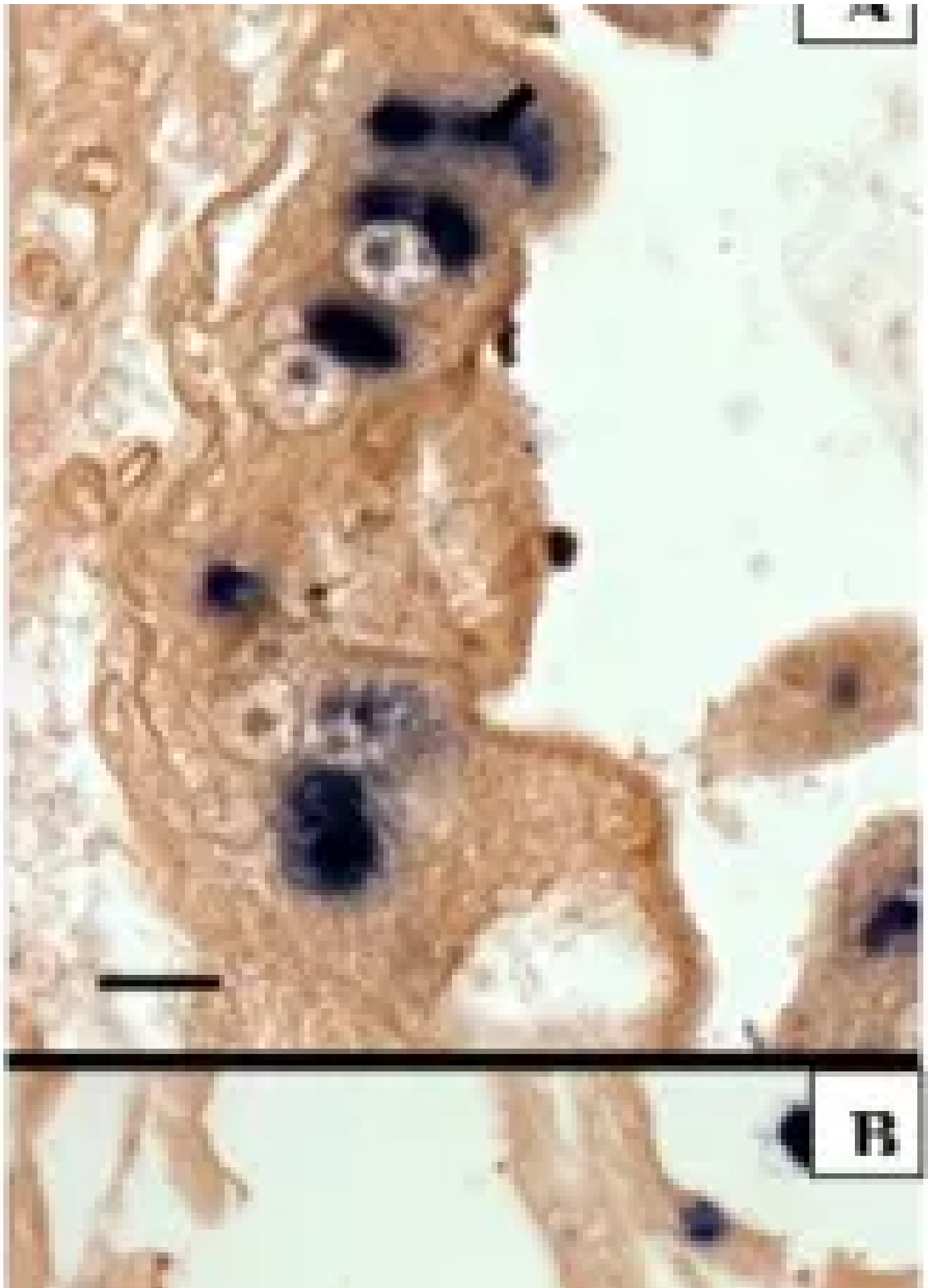

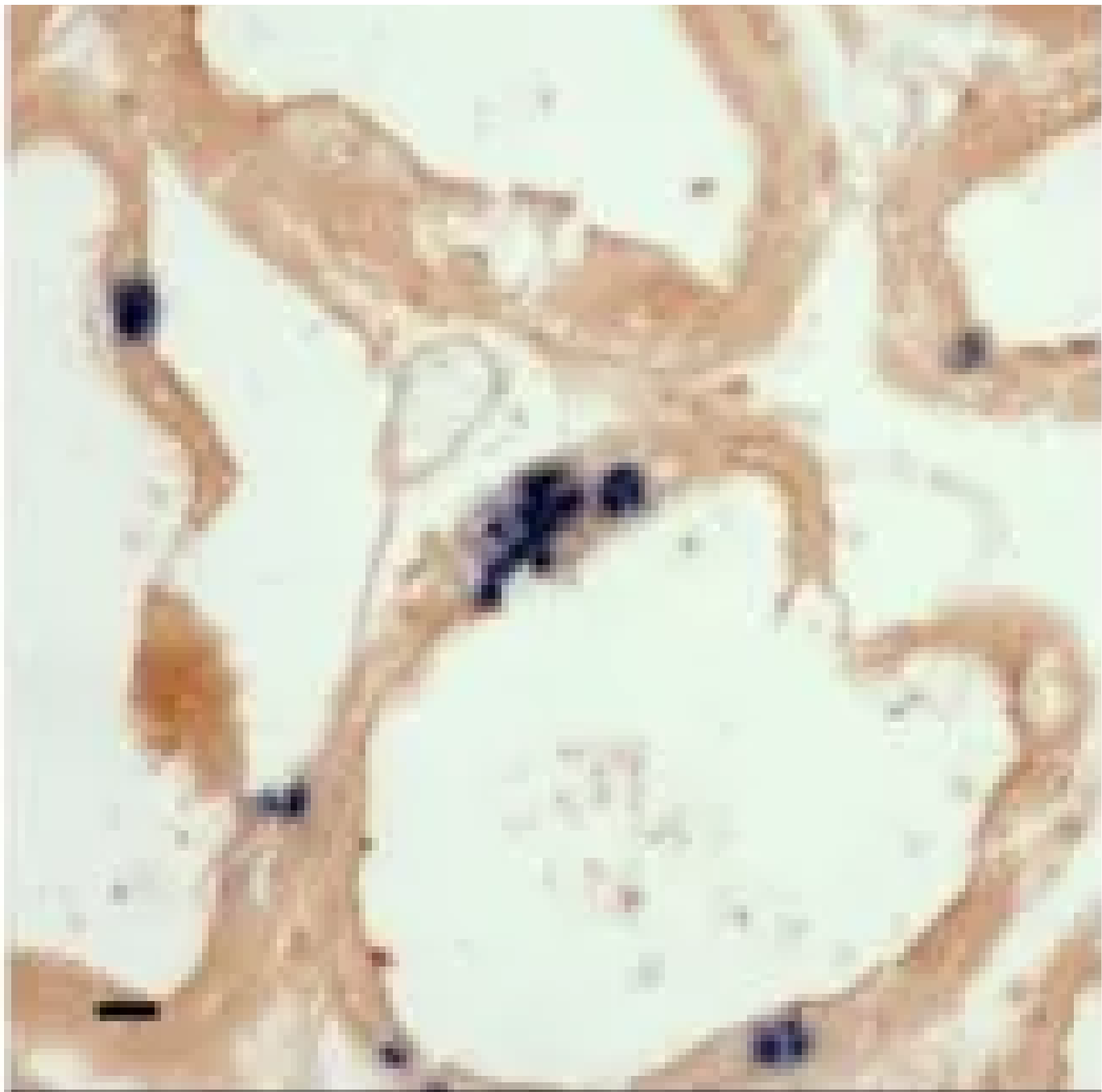
Fig. 1: H&E histology of *Enterocytozoon hepatopenaei* (EHP) in the infected shrimp. (A & B) hepatopancreas tissues of the *Penaeus vannamei*, (C) the *P. stylirostris*. Arrows indicate mature spores; stars indicate the plasmodia stage. (Scale bars = 25  $\mu$ m.)

## EHP PCR assay

We selected primers for detecting the EHP are EHP-510F (5'-GCCTGAGAGATGGCTCCCACG) and EHP-510R (5'-GCGTACTATCCCCAGAGCCCG) and PCR was performed with DNA extracted from EHP-infected shrimp. The results showed that this PCR can detect EHP-infected shrimp (Fig. 2, lane 1-3); the feces and water samples collected from infected shrimp tanks were also detected with EHP (Fig. 2, lanes 4 & 5). We also tested 2 other parasitic pathogens, an amoeba and the cotton shrimp disease microsporidium, but these EHP-primers did not cross react with them (Fig. 2, lane 6 & 7).







C

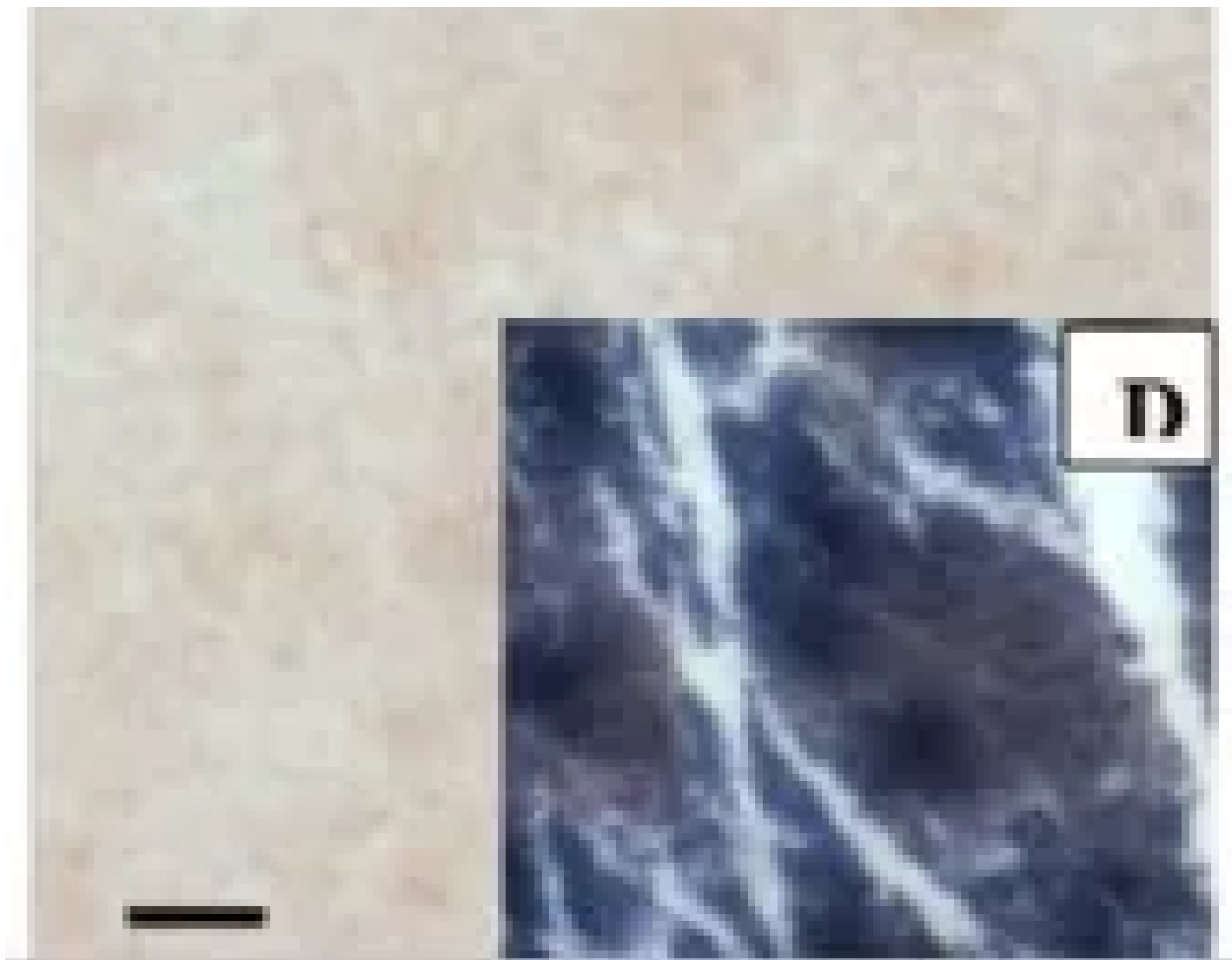


Fig. 4: In situ hybridization of the consecutive section with a digoxigenin-labeled EHP probe. The presence of dark blue precipitates indicates the presence of EHP (A) in situ hybridization in *Penaeus vannamei* (from Vietnam) with EHP probe; (B) *P. stylirostris* (Brunei); (C) *P. monodon* showing cotton shrimp disease (Madagascar), insert photo: ISH with a *Perezia penaei* probe. Scale bars = 25  $\mu$ m.

Unexpectedly, we detected EHP in 4 out of 9 samples of frozen *Artemia* biomass (Fig. 2, lane 9, a representative sample). From EHP-positive *Artemia* biomass, its 18S rRNA gene was amplified and sequenced, and the fragment was 99.9 percent identical to that of EHP from Vietnam, suggesting the EHP present in *Artemia* biomass may have originated from Southeast Asia.

## Studies of EHP transmission

Three bioassays were conducted using a population of EHP-infected shrimp sent from Thailand. In bioassay no. 1 (co-habitation group), diseased shrimp were transferred into a tank stocked with SPF shrimp tagged with visible elastomers. The SPF shrimp became infected after 35 days of co-habitation (Fig. 3A). For bioassay no. 2 (water-born infection group), only water was transferred from diseased shrimp tank into the SPF shrimp tank. The SPF shrimp were not affected even after 42 days (Fig. 3A). For bioassay no. 3, SPF shrimp were fed the hepatopancreas from the diseased shrimp. Samples were analyzed by PCR analysis every 5 days; SPF shrimp became infected at day 15 (Fig. 3B), suggesting that EHP can be transmitted via cannibalism.



## In situ hybridization (ISH)

By ISH with a digoxigenin-labeled EHP probe, the infected *P. vannamei* (Fig 4A) and the *P. stylirostris* (Fig 4B) showed the presence of microsporidium spores (basophilic inclusions) within the hepatopancreas, the tubule epithelial cells. The probe appears to be highly specific. No reaction was seen with *Perezia penaei*-infected *P. monodon* showing a clinical sign of cotton shrimp disease (Fig 4C).

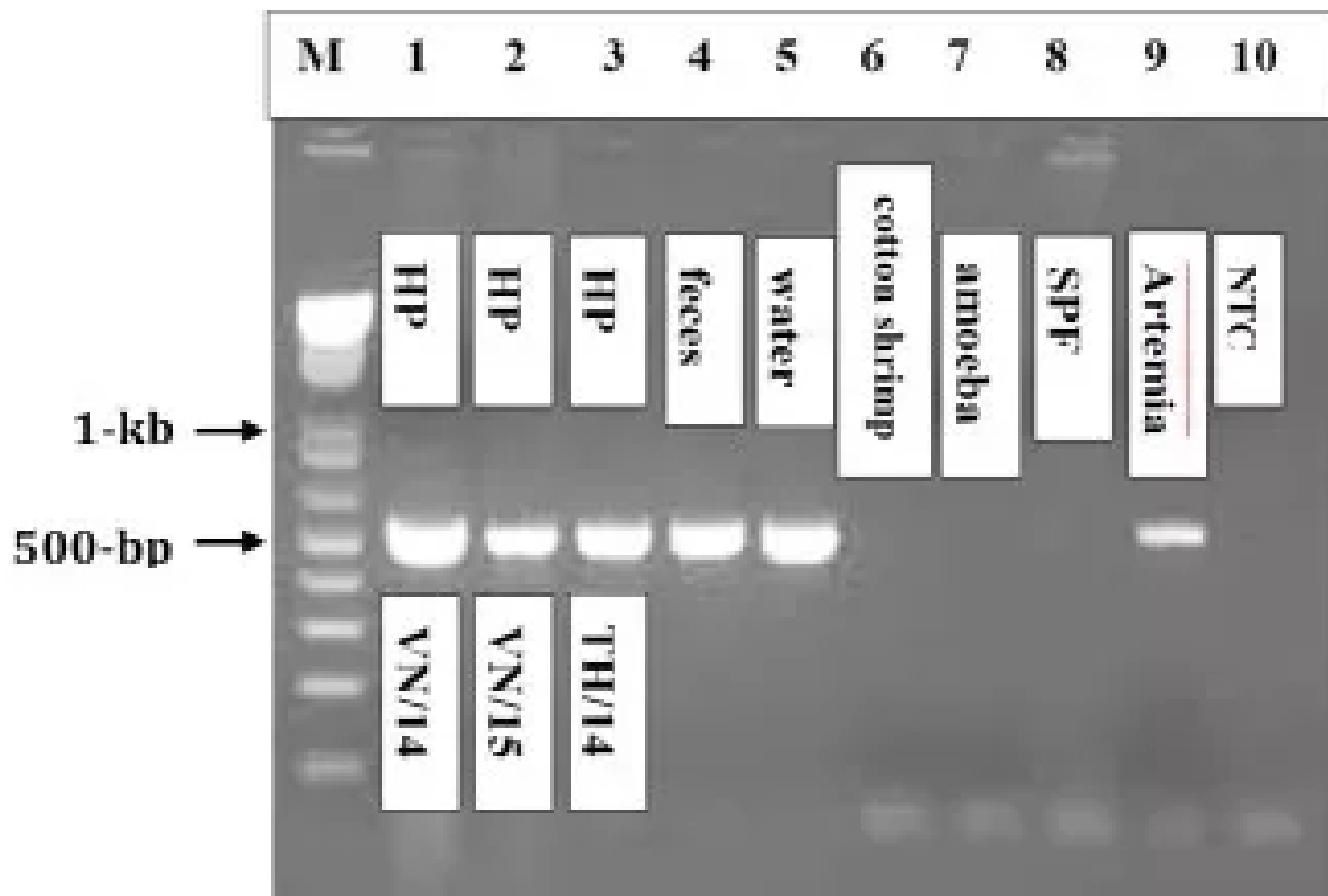


Fig. 2: PCR detection of *Enterocytozoon hepatopenaei* (EHP). M: 1 kb plus ladder molecular weight marker. The *Penaeus vannamei* collected in Vietnam (lane 1, 2014 sample; lane 2, 2015 sample) and from Thailand (lanes 3-5, hepatopancreas, feces and water), the *P. monodon* with cotton shrimp disease (lane 6), the *P. vannamei* with an amoeba (lane 7), SPF *P. vannamei* (lane 8), *Artemia* biomass (lane 9), none-template control (Lane 10).

## Perspectives

Concerns of EHP infections in farmed shrimp populations are likely to continue, creating a need to reduce risk through the establishment of effective means to control and monitor this parasite. In this regard, the use of specific and sensitive molecular methods for the detection of EHP in shrimp, live feeds, and the pond environments will likely prove to be very important. EHP-infected shrimp cannot be determined by simple visual inspection; there are no obvious clinical signs of

infection. Diagnostic protocols, based on PCR and ISH, developed in this study have proven to be both specific and sensitive, thus providing valuable tools for routine diagnosis and monitoring of shrimp stocks, pond environments and aquaculture commodities.

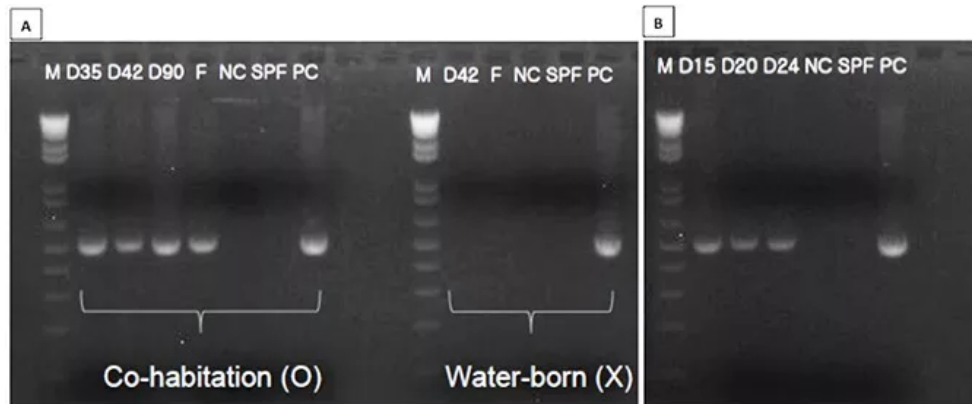


Fig. 3: PCR detection of *Enterocytozoon hepatopenaei* (EHP) in the hepatopancreas samples from bioassay no. 1, 2, and 3. (A) EHP was detected in the co-habitation group after Day 35, but not detected in water-born infection group. (B) EHP was detected 15 days after EHP infection (cannibalism).

## Authors



### JEE EUN HAN, PH.D.

Postdoctoral Research Associate  
School of Animal and Comparative Biomedical Sciences  
University of Arizona  
Tucson, AZ 85721 USA

[jeehan@u.arizona.edu](mailto:jeehan@u.arizona.edu) (<mailto:jeehan@u.arizona.edu>)



**KATHY F.J. TANG, PH.D.**

Associate Research Professor  
School of Animal and Comparative Biomedical Sciences  
University of Arizona  
Tucson, AZ 85721 USA

[fengjyu@email.arizona.edu](mailto:fengjyu@email.arizona.edu) (<mailto:fengjyu@email.arizona.edu>).



**DONALD V. LIGHTNER, PH.D.**

Professor Emeritus  
School of Animal and Comparative Biomedical Sciences,  
University of Arizona,  
Tucson, AZ 85721 USA

[dvl@u.arizona.edu](mailto:dvl@u.arizona.edu) (<mailto:dvl@u.arizona.edu>).

Copyright © 2016–2018  
Global Aquaculture Alliance